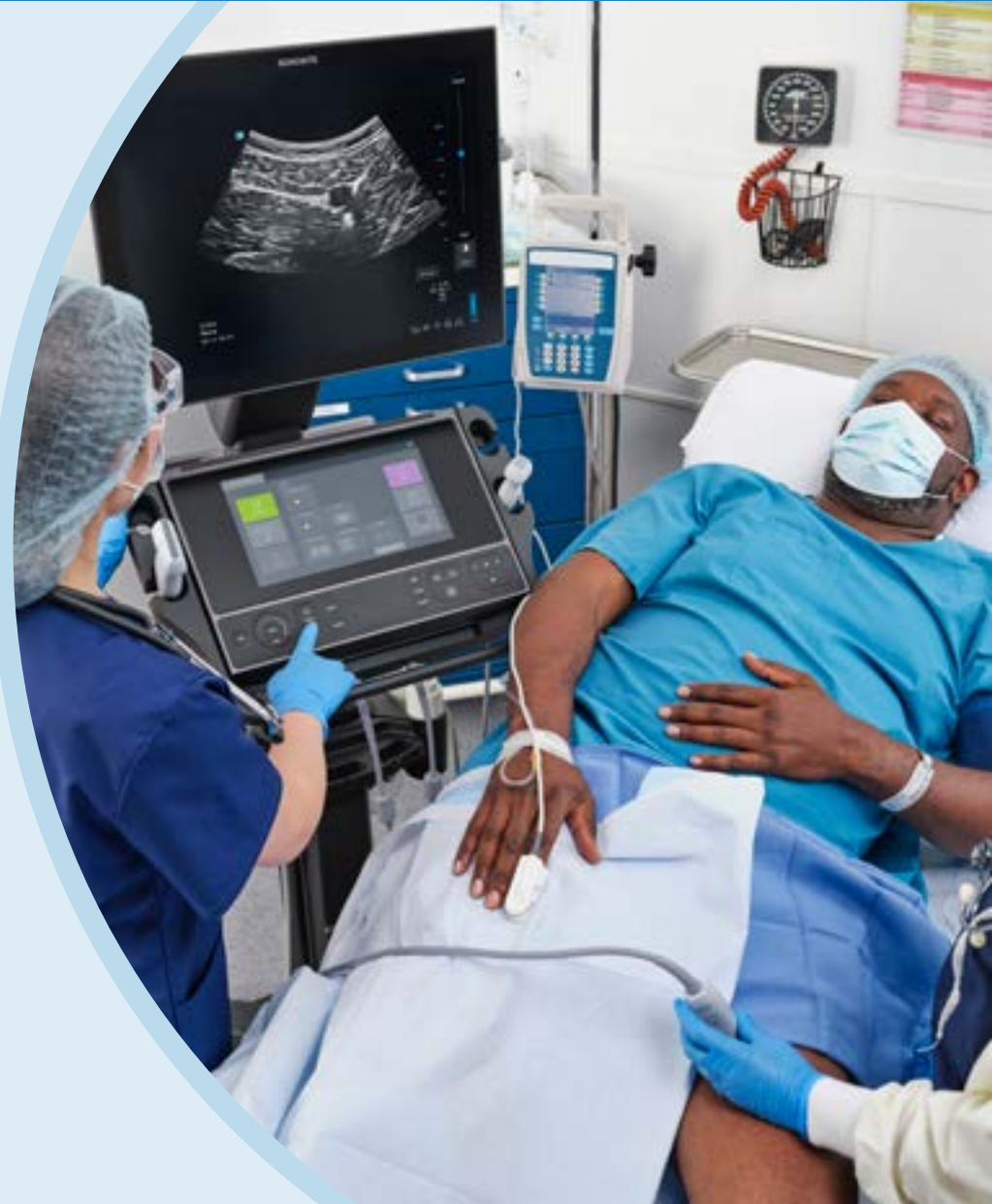

Adductor Canal Block Quick Guide

Any patient. Anywhere. Anytime.

Information contained in this document is meant for quick reference and a supplement to formal ultrasound experience, education or training.



Adductor Canal Block

Objective

Injection of local anesthetic lateral to the femoral artery within the adductor canal. The local anesthetic targets the Saphenous nerve located within the adductor canal at the mid thigh level.

Technique:

- Begin by slightly externally rotating the knee with the patient supine.
- Place the transducer in a transverse orientation midway between the patellar tendon and inguinal crease over the Sartorius Muscle.
- Identify the Femoral Artery and Vein within the Adductor Canal formed by the Sartorius Muscle (anterior wall), the Vastus Medialis (lateral wall) and the Adductor Longus (medial wall). The Saphenous Nerve is sometimes visualized within the canal.
- Use an in-plane lateral to medial approach with the block needle. The initial injection should occur lateral to the Femoral Artery within the Adductor Canal.

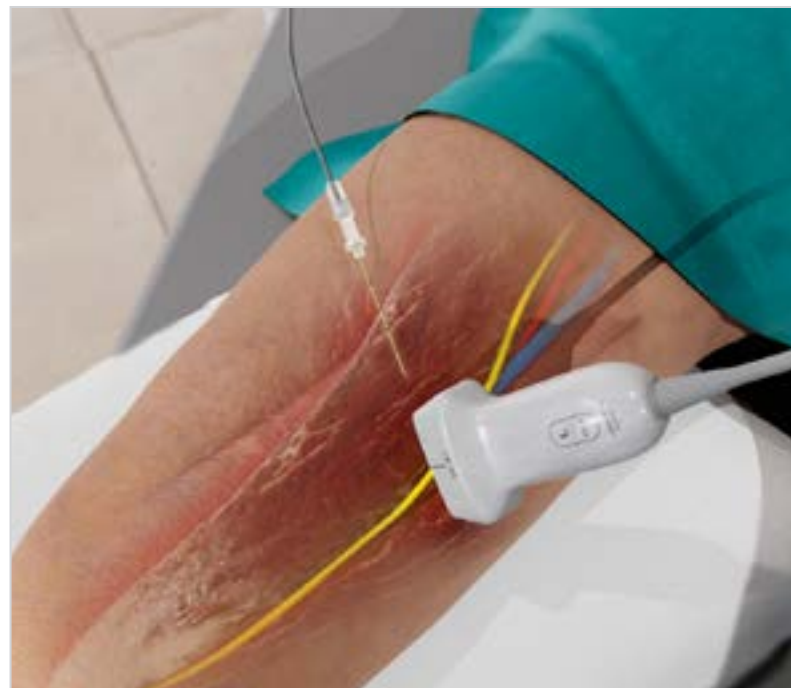

FIG. 1: Supine, Knee Position and Transducer Location

Clinical Pearls

Patient Positioning:

Supine, knee slightly externally rotated

Transducer:

L12-3, L15-4

Teaching Points:

- The Adductor Canal Block is a sensory only block targeting the Saphenous Nerve which should allow for early ambulation postoperatively.
- In addition to injection of local anesthetic lateral to the femoral artery, it may be beneficial to inject local anesthetic medial to the femoral artery via hydrodissection between the Sartorius muscle and Femoral Artery. This may ensure a more complete consistent block.
- Care should be taken not to perform the Adductor Canal Block too proximal. This may result in a block of the Femoral Nerve if a high volume of local anesthetic is used.

The Nerve to the Vastus Medialis may be visualized lateral to the Adductor Canal. Care should be used to avoid injury to this nerve with the block needle on approach to the Adductor Canal. You may choose to block this nerve if visualized.

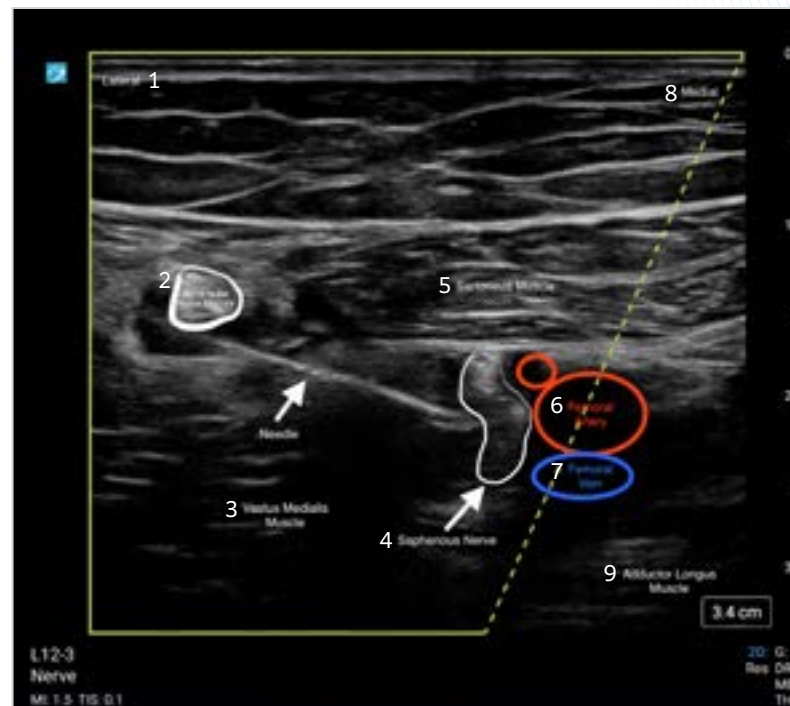


FIG. 2

- | | |
|---------------------------------|---------------------------|
| 1. Lateral | 6. Femoral Artery |
| 2. Nerve to the Vastus Medialis | 7. Femoral Vein |
| 3. Vastus Medialis Muscle | 8. Medial |
| 4. Saphenous Nerve | 9. Adductor Longus Muscle |
| 5. Sartorius Muscle | |

Any patient. Anywhere. Anytime.

FUJIFILM Sonosite, Inc.

Worldwide Headquarters

21919 30th Drive SE, Bothell, WA 98021-3904

Tel: +1 (425) 951 1200 or +1 (877) 657 8050

Fax: +1 (425) 951 6800

sonosite.com

This material is intended for healthcare professionals and not for patients or consumers. The information in this material is provided for general educational purposes, as a convenient quick reference and a supplement to professional experience, education and training, and should not be considered the exclusive source for this type of information. This material does not replace or supersede device labeling, including instructions for use, which accompanies any FUJIFILM Sonosite product. At all times, it is the professional responsibility of the practitioner to exercise independent clinical judgment in each particular situation. FUJIFILM assumes no responsibility or liability for any misuse of this material. FUJIFILM Sonosite would like to thank Dr. Daniel G. Malone, MD, RMSK, FACR for his contributions to this program.

SONOSITE and the SONOSITE logo are registered and unregistered trademarks of FUJIFILM Sonosite, Inc. in various jurisdictions. FUJIFILM is a registered trademark of FUJIFILM Corporation in various jurisdictions. All other trademarks are the property of their respective owners.

Copyright © 2024 FUJIFILM Sonosite, Inc. All rights reserved. Subject to change.